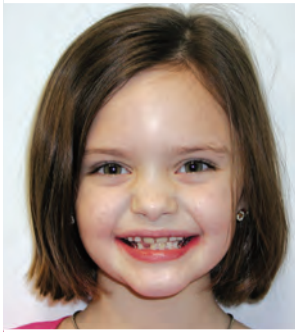


# YOUR GUIDE TO A HEALTHY SMILE



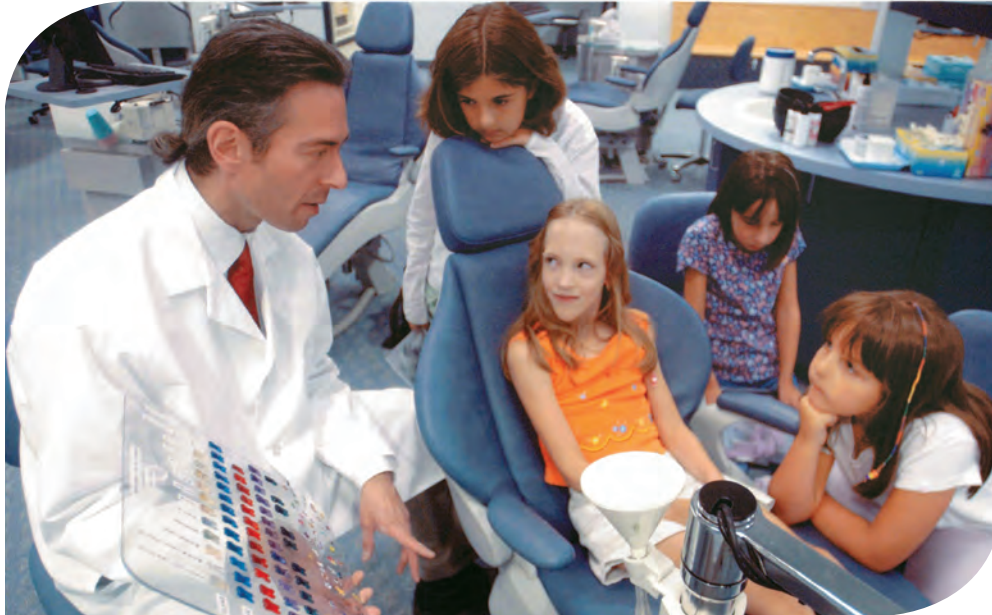*Dr. Peter T. Bronsky, Board Certified Specialist in Orthodontics*



## **BRONSKY ORTHODONTICS**

*Twenty-Five Plus Years of  
Orthodontic Excellence*

# YOUR GUIDE TO A HEALTHY SMILE



All of the patients included in *Your Guide to a Healthy Smile* were orthodontic patients treated by Dr. Peter T. Bronsky.  
Copyright © 2011 by Bronsky Orthodontics, P.C.



# TABLE OF CONTENTS



*Part I. Profile of Dr. Bronsky.....4*



*Part II. Pediatric Treatment.....10*



*Part III. Adolescent Treatment.....34*



*Part IV. Adult Treatment.....56*

# DR. PETER T. BRONSKY

## *Board Certified Specialist in Orthodontics*

### EDUCATION

- A native of the Southern Tier of New York.
- Graduate of the Medical College of the Virginia School of Dentistry.
- Residency in Orthodontics and a Master's of Science Degree in Anatomy from the University of North Carolina at Chapel Hill.
- Educated by the professors who wrote the text "**Contemporary Orthodontics**" and Dr. Bronsky contributed to the first edition.

### RESEARCH—BIOLOGICAL SCIENCE

- Studies involving normal facial development and malformations caused by genetic and environmental factors.
  - Publishes his research and presents at national and international meetings.
  - Research activity at the cutting edge of normal and abnormal facial development.


### RESEARCH—CLINICAL APPLICATIONS

- 25 years of scientific research while practicing orthodontics. Dr. Bronsky's facial development studies provide a unique perspective in the diagnosis and treatment of the orthodontic problems of his patients.



# PETER T. BRONSKY D.M.D. M.S.


*Practicing Orthodontics in his  
home area for over 25 years*



**DOCTOR**



**RESEARCHER**



**TEACHER**

# WHY BE TREATED BY A BOARD CERTIFIED SPECIALIST IN ORTHODONTICS?

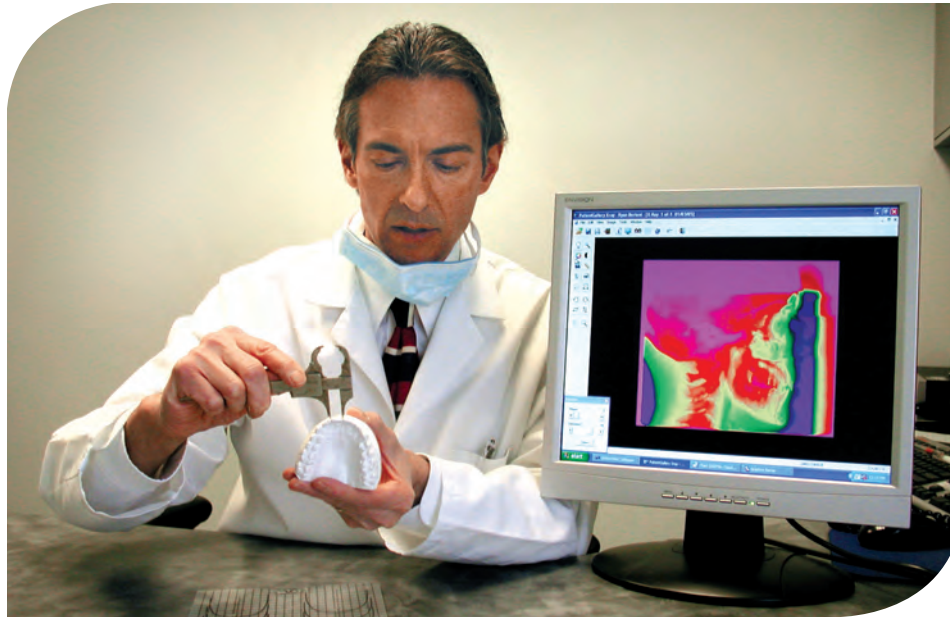
The greatest benefit is the confidence that you are being treated by a doctor who has successfully completed additional in-depth orthodontic study after receiving a dental degree and has been formally observed and examined by peer orthodontists. This additional training in the diagnosis and treatment of children, adolescents, and adults with a wide variety of problems, distinguishes the certified orthodontist from others.

Think of it this way, if you have a specific health issue such as a joint problem, you see an orthopedic specialist and expert, rather than a general practitioner. The Board Certified Orthodontist is the expert in treating tooth and jaw problems that require a specialist. Orthodontics is more than just straightening teeth by placing braces. It requires special knowledge to determine a diagnosis followed by formulation of an individualized treatment modality for each person's unique orthodontic problem.

Dr. Peter T. Bronsky's treatment provides the foundation for a lifetime of excellent oral health and a beautiful smile.



# STUDYING PATIENT X-RAYS AND TOOTH MODELS



*Essential to a Proper Diagnosis and  
Customized Treatment Plan*



# *Bronsky Orthodontic Treatment Systems*

---

**DESIGNED BY DR. PETER T. BRONSKY  
FOR DISTINCTIVE AGE GROUPS  
WITH DIFFERENT NEEDS**

---

*Pediatric • Adolescent • Adult*

# BRONSKY ORTHODONTIC PEDIATRIC TREATMENT

---

## *Why Orthodontics for Children?*

---

### **The benefits of timely orthodontic treatment:**

- Influence jaw growth in a positive manner,
- Guide permanent teeth into more favorable positions,
- Create functional bites of front and side teeth,
- Preserve or gain space for erupting permanent teeth, and
- Reduce likelihood of impacted permanent teeth.
- Reduce the need to extract permanent teeth,
- Lower the risk of trauma to protruded front teeth,
- Improve speech development,
- Correct harmful oral habits such as thumb and finger sucking, and
- Improve esthetics and self-esteem.

# THE ROLE OF THE ORTHODONTIST IN PEDIATRIC HEALTH CARE

Children with inherited mismatched jaws or tooth size discrepancies (crowding or spacing) benefit from an **initial orthodontic evaluation by age seven.**

These orthodontic problems, left untreated, often lead to compromised dental health, self-image problems and possible life-long facial deformities.

It is often critical to correct the orthodontic problems by reshaping a child's face and smile during the pediatric years.

**Dr. Peter T. Bronsky** is uniquely qualified by training as an orthodontist and researcher in facial growth and development to evaluate orthodontic problems in children.

*“My front teeth have a gap and stick out.”*

—PATIENT'S CONCERNS

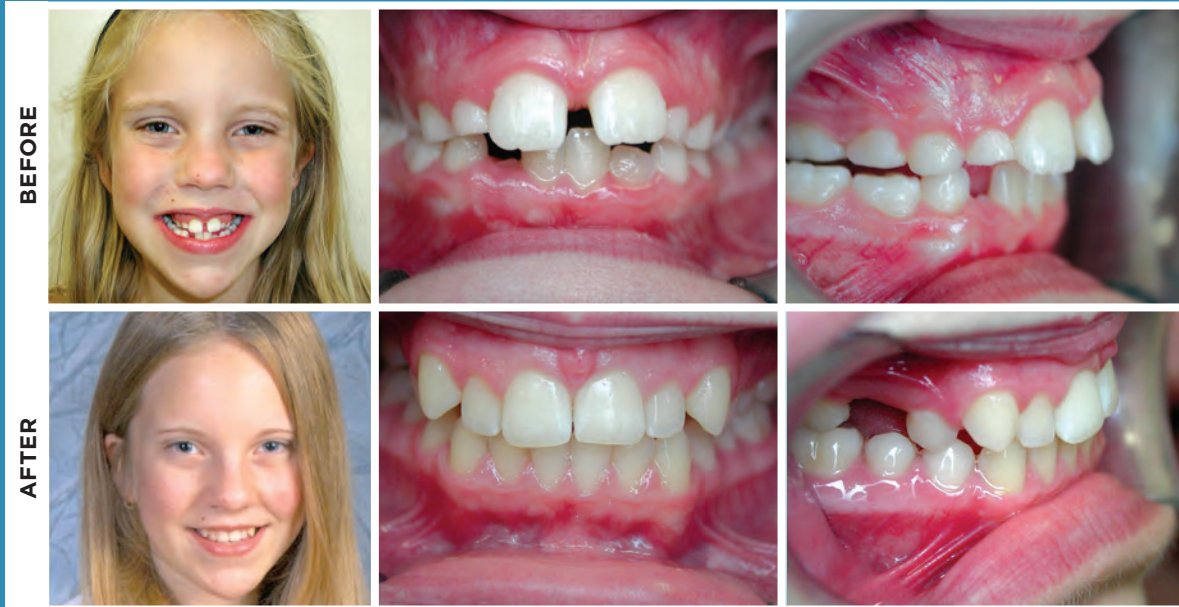## Orthodontic Problem List (Before)

- **Narrow** upper **jaw** resulting in a **crossbite** of the side teeth,
- **Protruded** (“sticking out”) and **spaced** upper front **teeth**,
- Upper **crowding** with insufficient space for adult tooth eruption, and
- **Excessive gum** display at full **smile**.

## Treatment Accomplishments (After)

- Widening of upper jaw and correction of crossbite,
- Closure of space between upper front teeth with retraction,
- Reduction in crowding while aiding in eruption of adult teeth, and
- Significant improvement of smile with removal of gum display.





*“Thanks for giving me such a nice smile for my school pictures.”*

—PATIENT’S COMMENT

## *“Thumb-sucking and open bite.”*

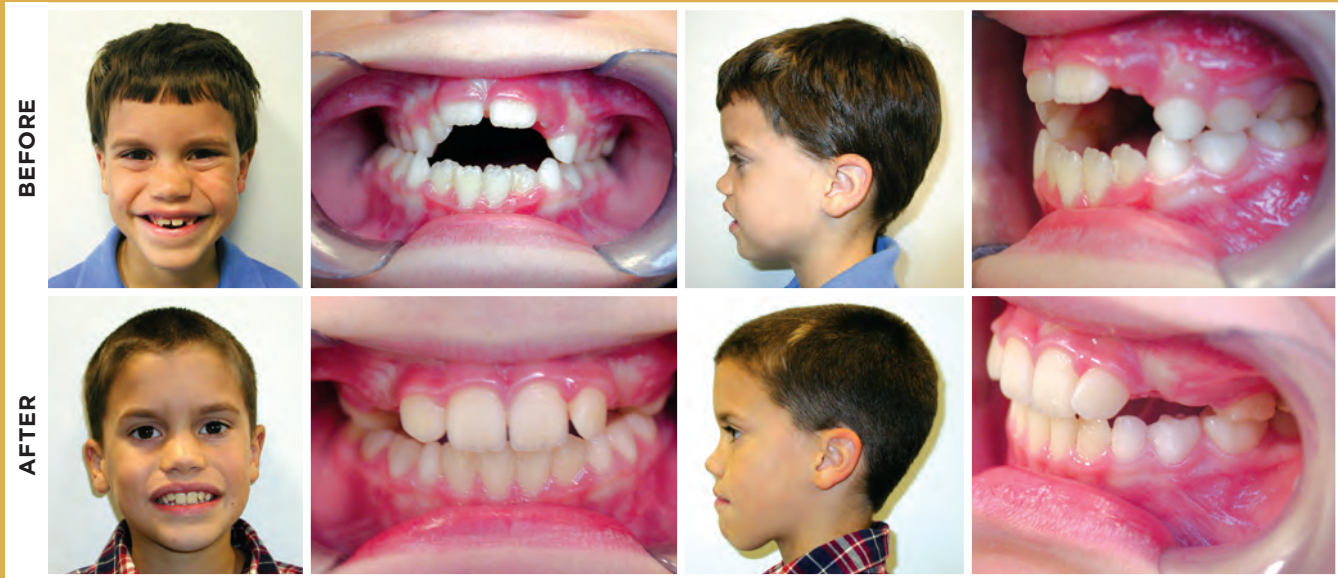—PARENT AND DENTIST CONCERNS

### **Orthodontic Problem List (Before)**

- **Narrow upper jaw** with **crossbite** (upper teeth biting inside lower) on right side,
- Severe **open bite** with **thumb-sucking** habit,
- **Retruded upper jaw** resulting in deep ‘smile grooves’, and
- **Retruded nasal bone** with prominent forehead.

### **Treatment Accomplishments Utilizing Dentofacial Orthopedics (After)**

- Widening of upper jaw resulting in crossbite correction,
- Closure of open bite with elimination of thumb-sucking habit,
- Acceleration of forward growth of the upper jaw and nasal bone, resulting in reduction of ‘smile grooves’ and forehead prominence.



*“I can now bite with my front teeth  
and chewing is a lot easier.”*

—PATIENT’S COMMENT

## BRONSKY ORTHODONTICS

*“My daughter has a crossbite and she is ‘chipping away’ her baby teeth. Our dentist said she has crowding and will not have enough room for her adult teeth.”*

—PARENT’S CONCERNS

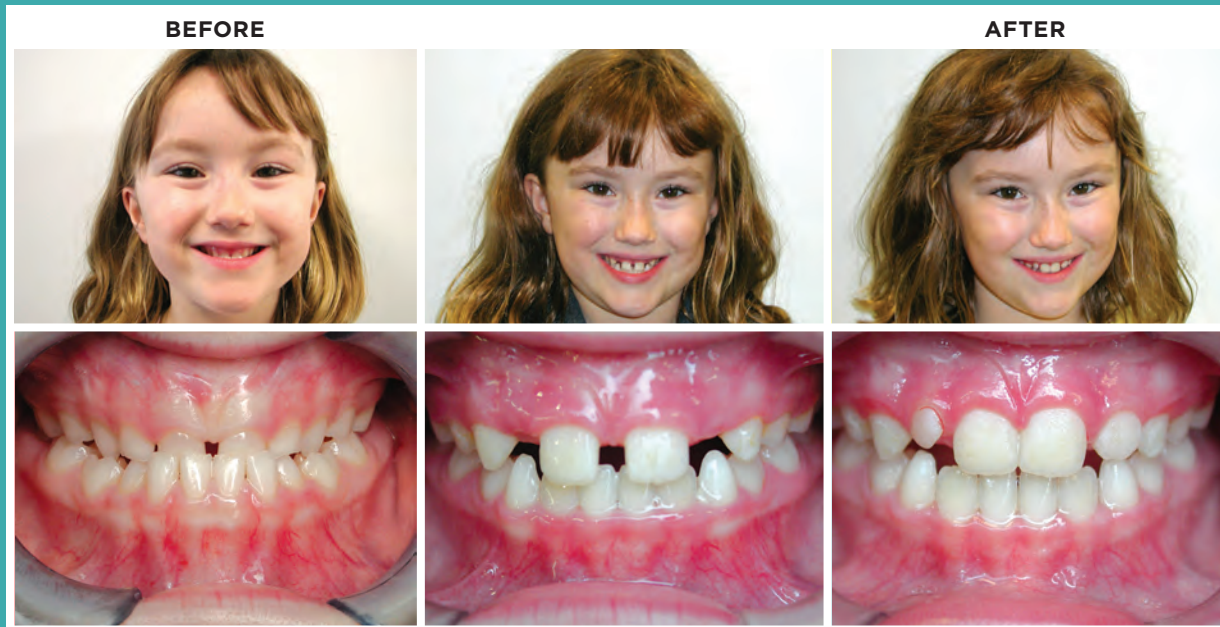### Orthodontic Problem List (Before)

- **‘Underbite’** with **retruded** (“too far back”) **upper jaw** and **protruded lower jaw**,
- **Narrow upper jaw** with **crossbite** of side teeth,
- Significant **space** between **upper front teeth** without ability for eruption of side incisors,
- Initial smile is ‘narrow’ and does not show front teeth, and
- Intermediate smile displays space between upper front teeth.

### Treatment Accomplishments (After)

- Improvement in three-dimensional relationships of upper and lower jaws,
- Correction of crossbite of front and side teeth,
- Closure of space between adult center front teeth to aid in eruption of side incisors, and
- Progressive improvement in smile esthetics.

## PEDIATRIC TREATMENT



*“I am really pleased that our dentist recognized the severity of my daughter’s orthodontic problems and sent us for an evaluation when he did.”*

—PARENT’S COMMENT

*“My front teeth are sticking out and have big spaces.”*

—PATIENT’S CONCERNS

### Orthodontic Problem List (Before)

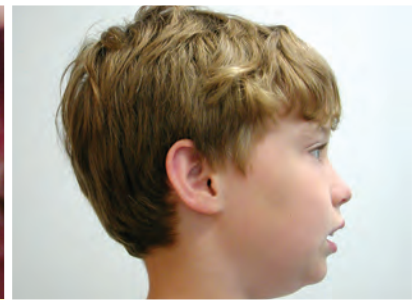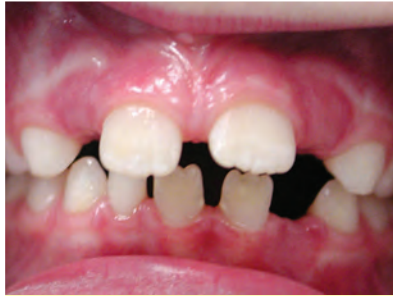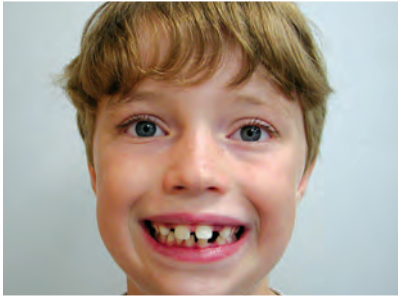- Upper and lower **front tooth spacing**,
- **Protrusion** of upper **front teeth** with high risk of injury and difficulty in obtaining lip closure,
- **Lower jaw skeletal retrusion** (too far back) associated with tendency towards ‘double chin’, and
- **Traumatic non-functional bite** of side teeth.

### Treatment Accomplishments (After)

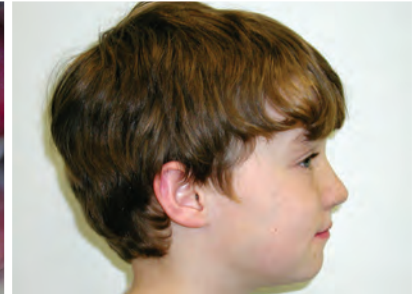
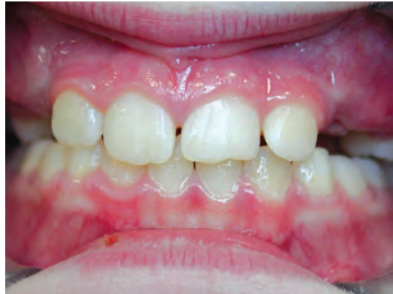- Closure of upper and lower front tooth spacing with smile enhancement,
- Retraction of upper front teeth, establishing a functional contact with lower front teeth and allowing for lip closure,
- Restriction of upper jaw growth and acceleration of lower jaw growth to balance facial profile, and
- Established functional bite of side teeth while awaiting eruption of remaining adult teeth.



BEFORE



AFTER



*“I really like my new smile and my friends  
can’t believe the change.”*

—PATIENT’S COMMENT

*“My upper front teeth are twisted and sticking out.”*

—PATIENT'S CONCERNS

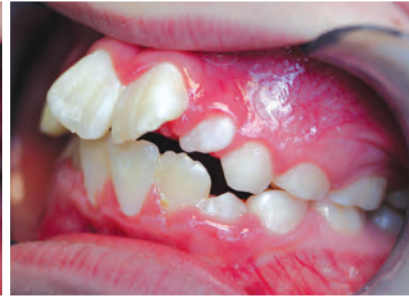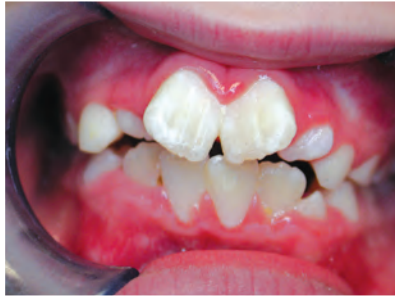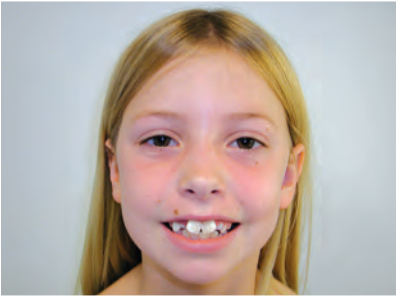### Orthodontic Problem List (Before)

- Upper and lower **tooth crowding** related to an inherited discrepancy between tooth and jaw size,
- **Narrow** upper and lower **jaw** dimensions,
- **Rotation** (“twisted”) of upper center **incisor teeth** with backward position of side incisor teeth, and
- All four **canine teeth** are **displaced** outward due to crowding.

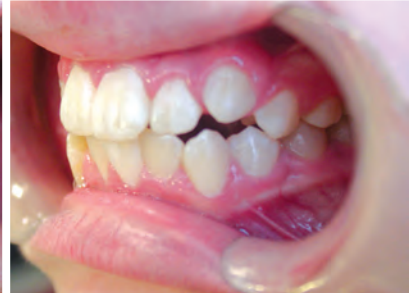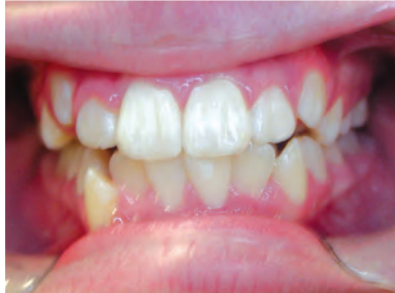### Treatment Accomplishments (After)

- Widening of upper jaw followed by alignment of upper front teeth, and
- Increasing space available for crowded teeth including the outwardly displaced canines that are now erupting.

BEFORE



AFTER



*“I love my new smile and just  
in time for school photos.”*

—PATIENT’S COMMENT

*“Why hasn’t my front tooth come in yet?  
My dentist said that I have a crossbite.”*

—PATIENT’S CONCERNS

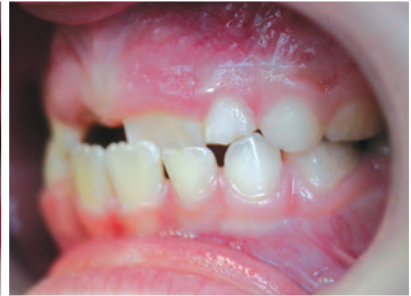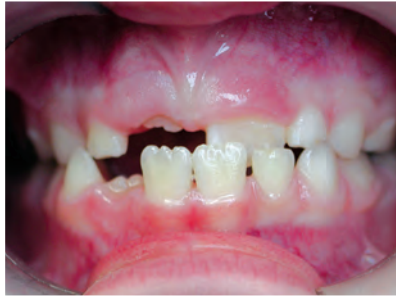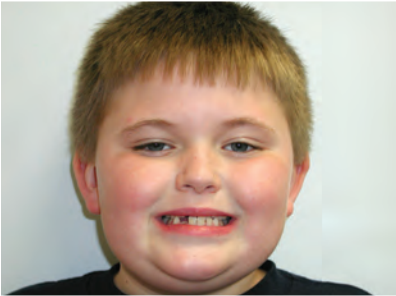### Orthodontic Problem List (Before)

- **Crossbite** of upper front teeth resulting in forward pressure on lower front teeth,
- **Narrow** upper and lower **jaws**,
- **Upper and lower** front tooth **crowding** with insufficient space for eruption of upper center and upper and lower side incisor teeth, and
- Upper front teeth not visible in his smile.

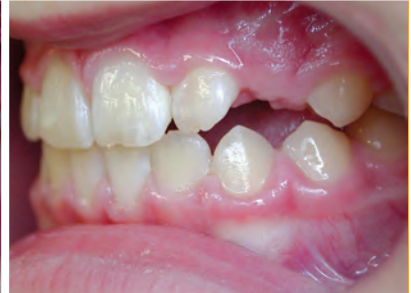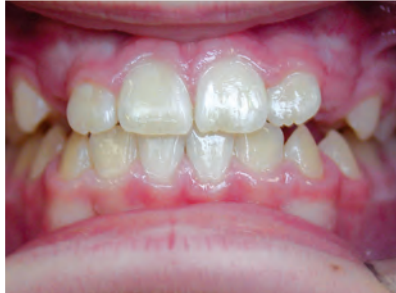### Treatment Accomplishments (After)

- Correction of front tooth crossbite and establishing functional contact with lower front teeth,
- Widening of upper and lower jaws,
- Repositioning of center front teeth to open space for side incisors that were displaced into a ‘second row,’ and
- Established an attractive smile with upper front teeth now visible.

BEFORE



AFTER



*“Thanks for helping get my front teeth in place—  
my mom says that I have a nice smile now.”*

—PATIENT’S COMMENT

## BRONSKY ORTHODONTICS

*“I have an overbite and I don’t like my smile.”*

—PATIENT’S CONCERNS

### Orthodontic Problem List (Before)

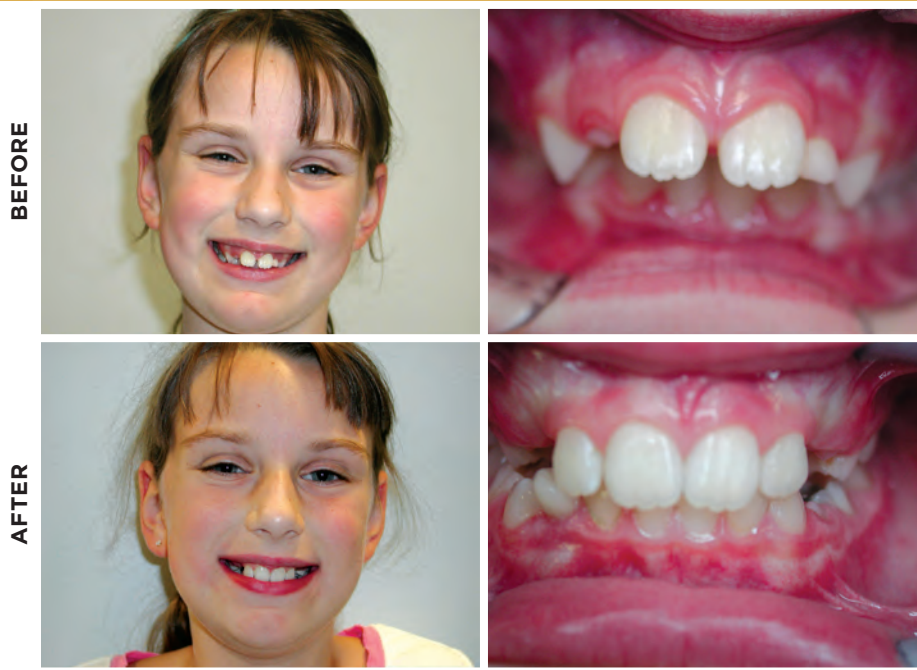- **Protruding and spaced upper front teeth** (with high risk of trauma),
- **Overbite** with lower front teeth biting into roof of mouth,
- **Short upper lip** resulting in excessive gum exposure at smile, and
- **Narrow upper jaw** with crowding.

### Treatment Accomplishments (After)

- Closure of upper front tooth spacing,
- Reduction in overbite,
- Widening of upper jaw and increase in space for adult teeth, and
- Improvement in smile with reduced gum exposure.



## PEDIATRIC TREATMENT



*“My teeth look and feel a lot better, thank you!”*

—PATIENT'S COMMENT

*“My front teeth stick out and my bottom teeth bite into the roof of my mouth.”*

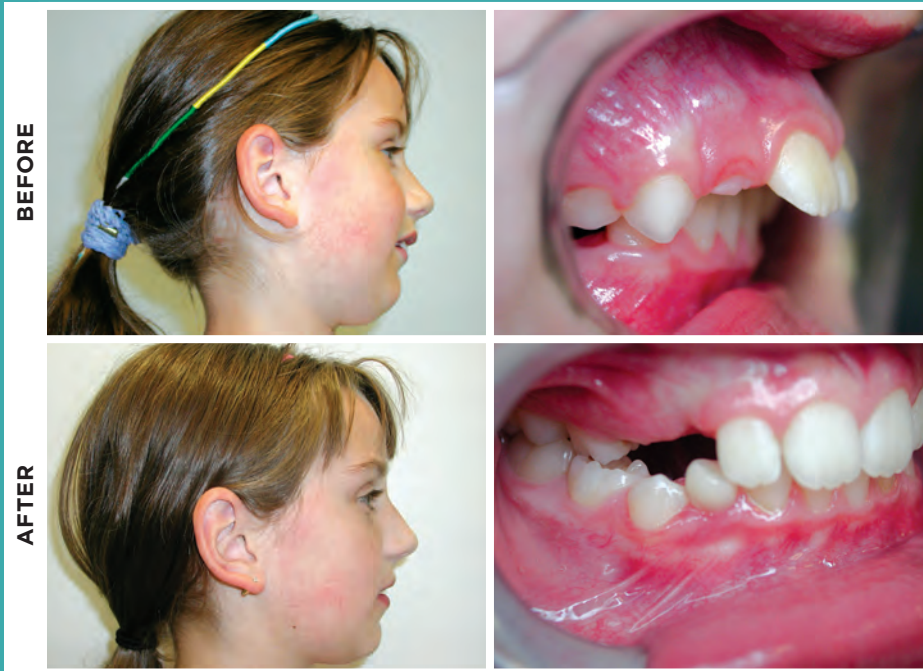—PATIENT'S CONCERNS

### Orthodontic Problem List (Before)

- Severe **protrusion** of upper front teeth with high likelihood of injury,
- **Overbite** with lower front teeth biting into roof of mouth,
- **Lower jaw retrusion** (too far back) with tendency toward a 'double chin',
- **Imbalance of facial and lip profile** with lower lip positioned behind upper front teeth, and
- **Traumatic bite** of side teeth correlated with jaw discrepancy.

### Treatment Accomplishments (After)

- Retraction of upper front teeth to prevent injury,
- Upper and lower jaw growth modification to improve facial profile and lip relationships,
- Established a functional bite of the adult first molars, and
- Increased space available for eruption of adult side teeth.



*“I sure can chew much better.”*

—PATIENT'S COMMENT

## BRONSKY ORTHODONTICS

*“As a dental assistant and mother I can see that my son has lots of problems that need to be corrected.”*

—PARENT'S CONCERNS

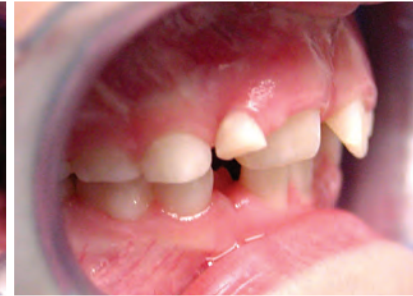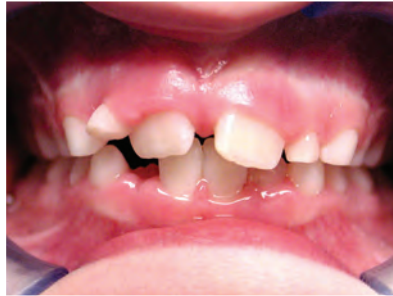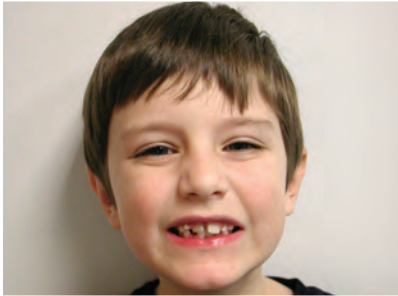### Orthodontic Problem List (Before)

- **Narrow upper jaw** and **retruded lower jaw**,
- **Spacing** and rotation of **upper center incisor teeth** with **side incisors displaced** into a 'second row' due to **crowding**,
- **Traumatic** non-functional **bite** of side teeth due to his **jaw discrepancy**, and
- **Crowding** of **lower front teeth** with side incisors in a 'second row'.

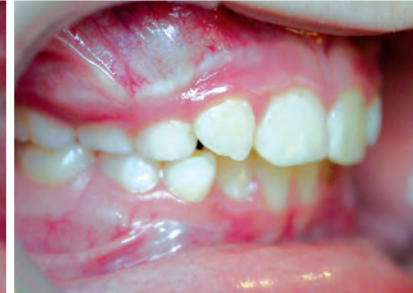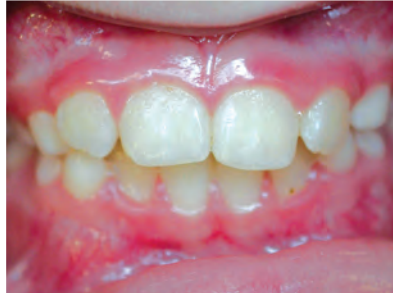### Treatment Accomplishments (After)

- Expansion of upper jaw,
- Closure of space between upper center incisors to allow for forward positioning of the side incisor teeth,
- Improvement in relationships of upper and lower jaws while establishing a functional bite of side teeth, and
- Improved alignment of lower front teeth.

BEFORE



AFTER



*“Thanks for taking such good care of my son  
and correcting his orthodontic problems.”*

—PARENT'S COMMENT

*“Thumb sucking has ‘caused’ a crossbite and open bite and his upper front teeth are twisted.”*

—MOTHER’S CONCERNS

### Orthodontic Problem List (Before)

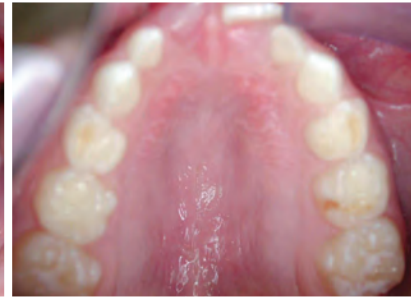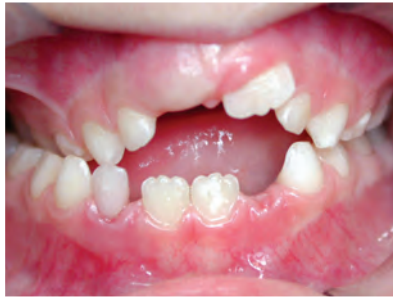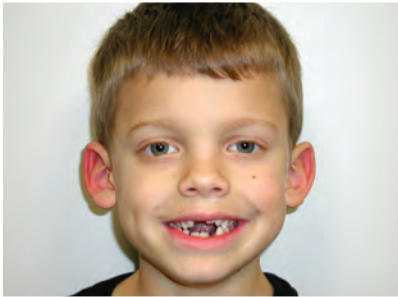- **Narrow upper jaw** with **crossbite** (upper teeth ‘biting’ inside lower) on right side **following lower jaw shift** due to traumatic bite of side teeth,
- Severe **open bite** with a **thumb-sucking** habit, and
- Moderate **upper tooth crowding** with rotated center incisor teeth and upper side incisors blocked from eruption.

### Treatment Accomplishments Utilizing Dentofacial Orthopedics (After):

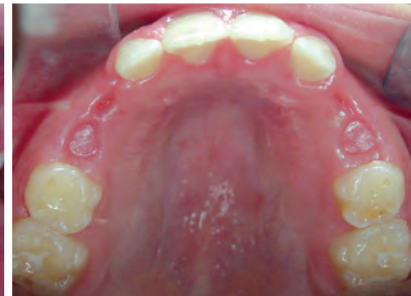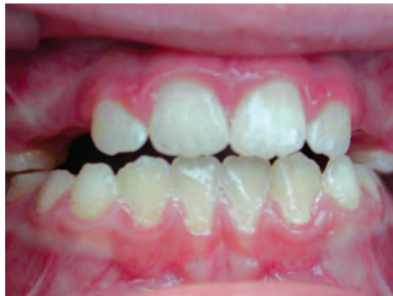- Widening of upper jaw and removal of lower jaw shift that could lead to uneven growth,
- Closure of open bite and correction of crossbite,
- Elimination of thumb-sucking habit in a ‘child-friendly’ manner, and
- Increased space to allow for eruption and alignment of crowded upper front teeth.



BEFORE



AFTER



*“I like my new smile,  
my teeth look really straight.”*

—PATIENT’S COMMENT

# INDIVIDUAL PROBLEMS CALL FOR *UNIQUE* SOLUTIONS

---

*“Do you think that I will  
need a retainer or braces?”*

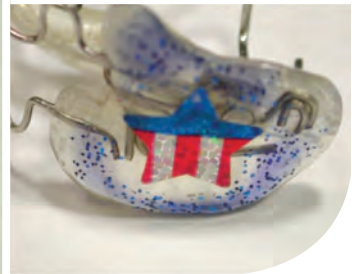
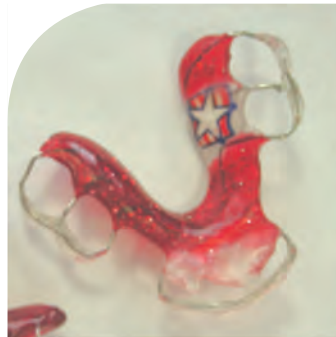
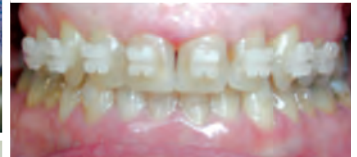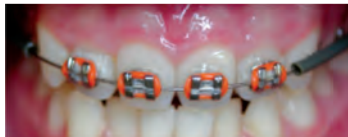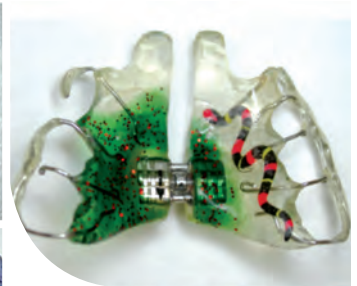---

Every patient at Bronsky Orthodontics undergoes a thorough evaluation to determine their orthodontic problems (diagnosis) followed by formulation of treatment objectives. An individualized treatment plan is then developed by Dr. Bronsky.

The ultimate decision related to the appropriate treatment methods is made at a meeting (consultation) based on the recommendation of Dr. Bronsky with input from the parents and patients.

Dr. Bronsky personally designs the treatment methods including all customized fixed and removable appliances, most of which are fabricated in our state-of-the-art orthodontic laboratory.

# CUSTOMIZED ORTHODONTIC TREATMENT APPLIANCES CREATED FOR OUR PATIENTS



# BRONSKY ORTHODONTICS ADOLESCENT TREATMENT

*“All my teeth are crooked and my dentist  
is worried about gum recession.”*

—PATIENT'S CONCERNS

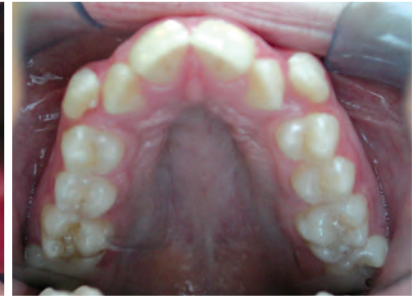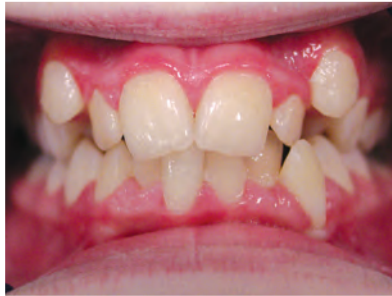## Orthodontic Problem List (Before)

- **Severe** upper and lower **crowding**,
- Outward **displacement** of upper **canines** and lower left canine,
- **Narrow V-shaped upper jaw**,
- **Gum recession** lower left canine secondary to crowding, and
- Dark spaces in corners of smile showing only upper front teeth.

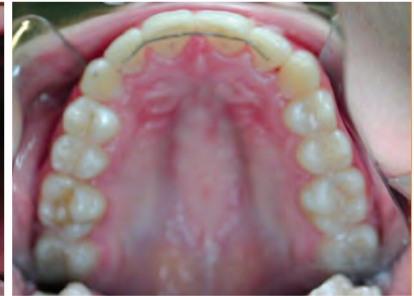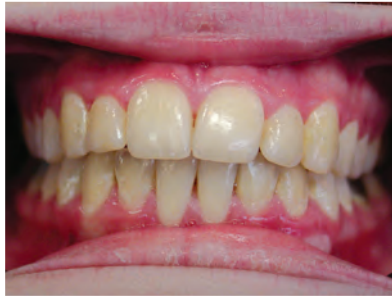## Treatment Accomplishments (After)

- Orthopedic expansion of upper jaw,
- Straightening of upper and lower teeth with inward positioning of canines,
- Improving bone support around prominent roots of lower teeth, and
- Creating a broad natural looking smile.

BEFORE



AFTER



*“My new smile looks great, I can’t believe that you could make my teeth so straight.”*

—PATIENT’S COMMENT

*“My son has too many teeth for the size of his mouth.”*

—PARENT’S CONCERNS

### Orthodontic Problem List (Before)

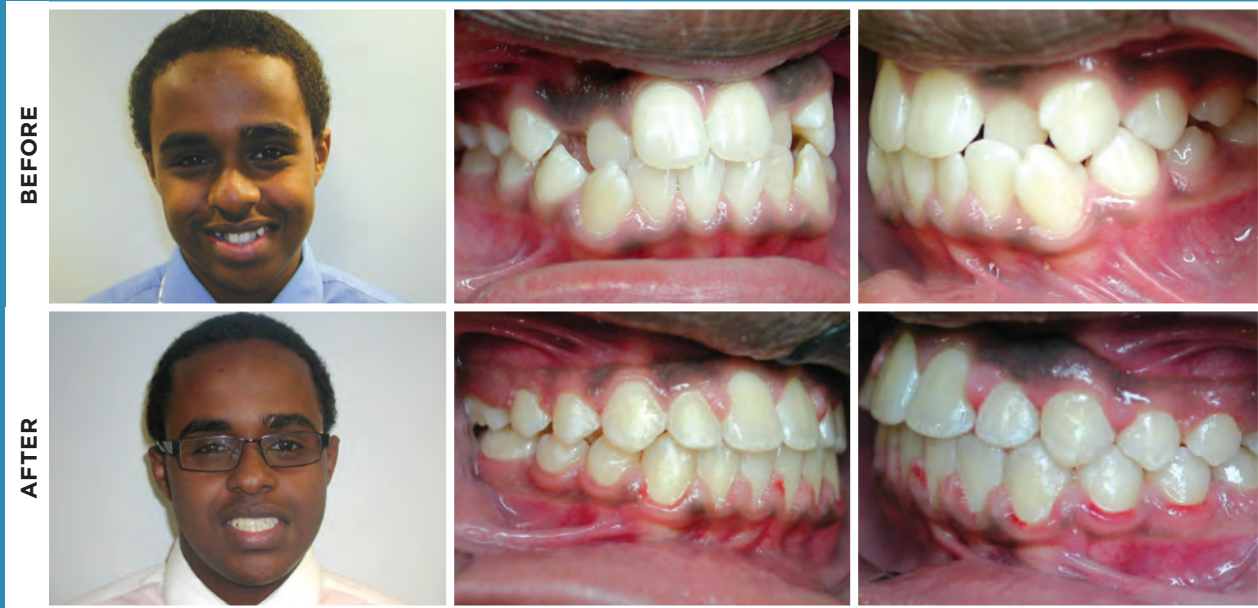- **Crossbite** of upper-side incisor teeth,
- Upper right **canine tooth impacted** (unable to erupt due to crowding),
- **Narrow upper jaw,**
- Upper left canine tooth and lower canine **teeth displaced** outward due to crowding, and
- **Irregular smile** due to uneven position of upper front teeth.

### Treatment Accomplishments (After)

- Correction of crossbite of upper-side incisor teeth,
- Creation of space to allow for positioning of impacted upper right canine,
- Repositioning of displaced canine teeth, and
- Creation of an ideal smile secondary to alignment of upper front teeth.



## ADOLESCENT TREATMENT



*“Everyone tells me that I have a nice smile, thank you!”*

—PATIENT’S COMMENT

## *“Overbite and crowding.”*

—PARENT’S CONCERNS

### **Orthodontic Problem List (Before)**

- **Overbite** with lower front teeth biting into the roof of his mouth,
- **Narrow upper** jaw and **retruded lower** jaw,
- **Crowding** with ‘tipped back’ and crossed center incisors and protruded upper side incisors, and
- Excessive **gum exposure** in smile with vertical ‘overgrowth’ of upper jaw.

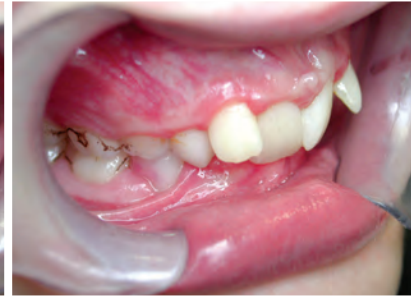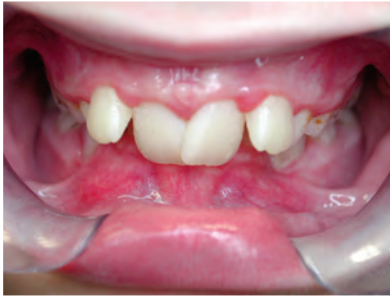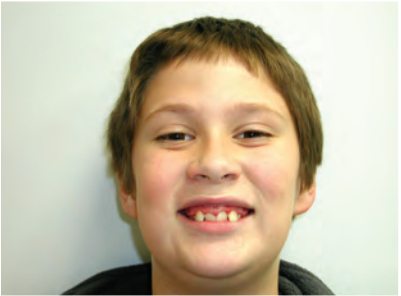### **Treatment Accomplishments (After)**

- Three-dimensional improvement in upper and lower jaw relationship,
- Corrected overbite and established ideal contact between upper and lower front and side teeth, and
- Enhanced smile esthetics with improved position of upper front teeth to lip.

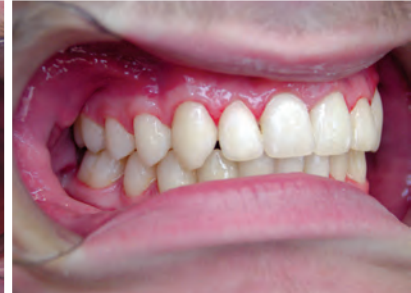
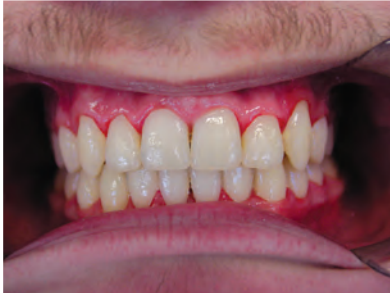
## ADOLESCENT TREATMENT

BEFORE



AFTER



*“Orthodontic treatment was a lot of work but it sure was worth it.”*

—PATIENT'S COMMENT

## BRONSKY ORTHODONTICS

*“I don’t like to smile with a missing front tooth. It’s hard to brush my teeth because they are so crooked.”*

—PATIENT’S CONCERNS

### Orthodontic Problem List (Before)

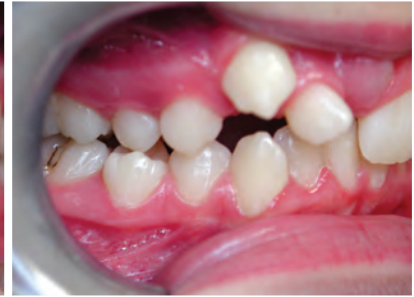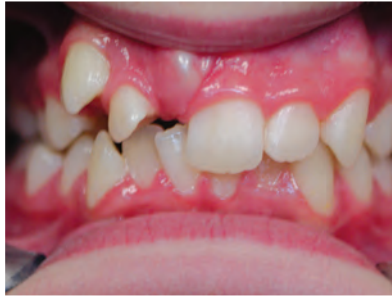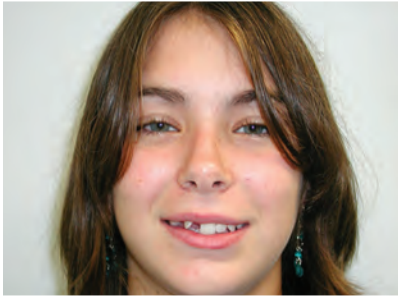- Upper right **center incisor** tooth is **blocked** from eruption,
- Upper right **side incisor** and **canine displaced** outward,
- **Overbite** with lower front teeth biting into roof of mouth,
- **Lower crowding** with tooth displacements resulting in ‘thin gum’ tissue, and
- **Traumatic** non-functional **bite** of right and left side teeth.

### Treatment Accomplishments (After)

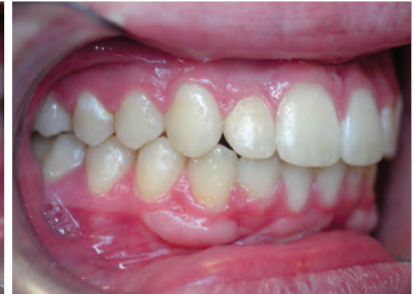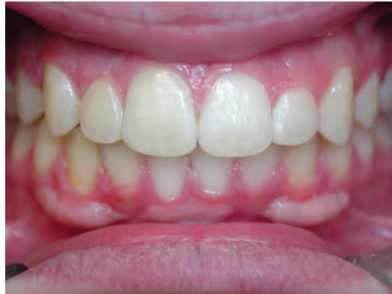- Straightened upper front teeth with positioning of blocked upper incisor,
- Corrected overbite of front teeth,
- Aligned lower teeth with positioning into center of bone,
- Established a functional bite of right and left side teeth, and
- Significantly improved smile esthetics.

## ADOLESCENT TREATMENT

BEFORE



AFTER



*“Thanks for giving my daughter such a beautiful smile.”*

—MOTHER’S COMMENT

*“My teeth are twisted and crowded.”*

—PATIENT'S CONCERNS

### Orthodontic Problem List (Before)

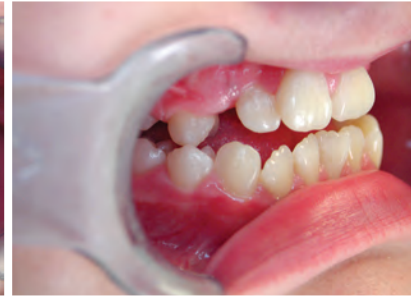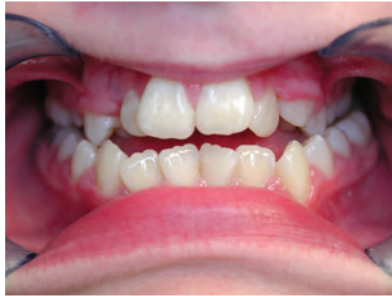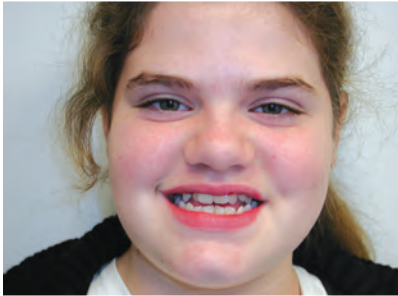- **Narrow** and **retruded** (set back) **upper jaw** with accentuated grooves on sides of nose,
- **Crowded** upper and lower **front teeth**, upper right canine blocked from eruption,
- **Open bite** without front tooth contact, and
- Excessive width of lower jaw with crossbite.

### Treatment Accomplishments (After)

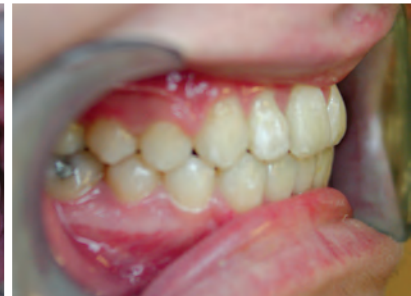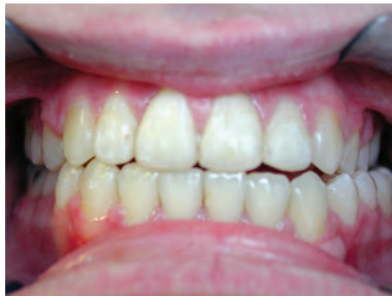- Expanded and protracted (forward positioned) upper jaw with improved upper lip support and reduction in nasal grooves,
- Straightened upper and lower front teeth while positioning upper right canine, and
- Achieved an attractive, natural-looking smile.

## ADOLESCENT TREATMENT

BEFORE



AFTER



*“I can’t stop smiling...thank you!”*

—PATIENT’S COMMENT

## BRONSKY ORTHODONTICS

*“My son’s teeth are everywhere but in the right place and our dentist said he has extra teeth blocking his upper front one from coming in.”*

—MOTHER’S CONCERNS

### Orthodontic Problem List (Before)

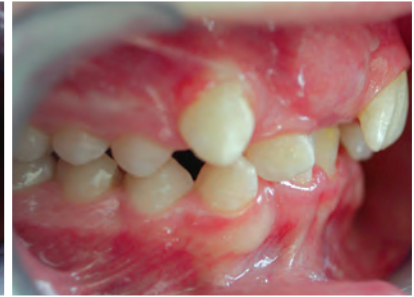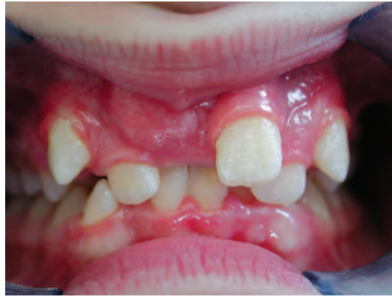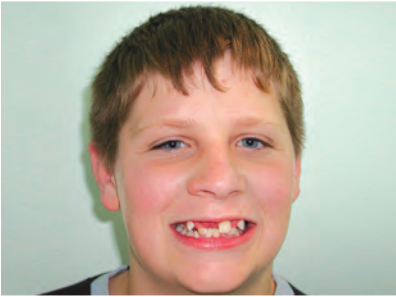- **Severe upper tooth crowding** with **impacted** center incisor and **displaced** upper canines and side incisors,
- **Overbite** with lower front teeth hitting into roof of mouth,
- Lower **crowding** with backward displacement of side incisors, and
- **Traumatic nonfunctional bite** of side teeth.

### Treatment Accomplishments (After)

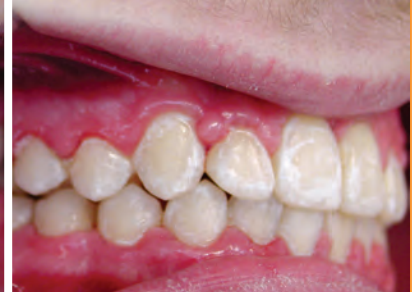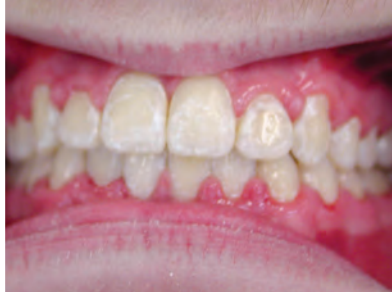- Straightened upper and lower front teeth with positioning of upper center incisor tooth,
- Corrected overbite with creation of ideal contact between upper and lower front teeth, and
- Improved ‘fit’ of side teeth with achievement of an ideal bite.

## ADOLESCENT TREATMENT

BEFORE



AFTER



*“I almost start to cry every time I look at my son’s smile.”*

—MOTHER’S COMMENT



*“Crowded lower front teeth that are hard to brush and twisted upper back teeth.”*

—PATIENT'S CONCERNS

### Orthodontic Problem List (Before)

- Severely **narrow** upper and lower **jaws** with **crowding** of teeth,
- **Traumatic bite** of 'side' teeth with **crossbite** and rotation of second premolars, and
- Inability to maintain good oral health due to difficulty with brushing and flossing.

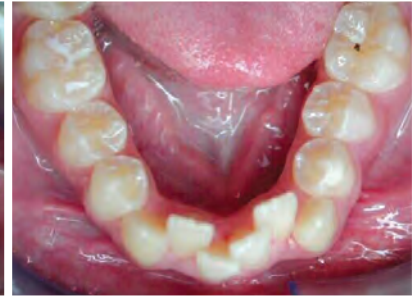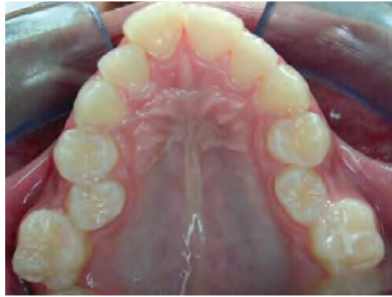### Treatment Accomplishments (After)

- Converted upper and lower dental arches from narrow V to U shape resulting in a broad natural-looking smile,
- Repositioned lower front teeth for improved alignment and stability,
- Aligned upper back teeth to improve bite, and
- Improved ability to brush and floss all areas, resulting in enhanced dental health.

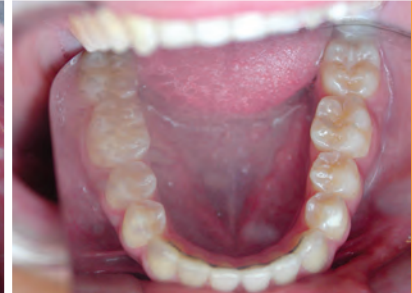
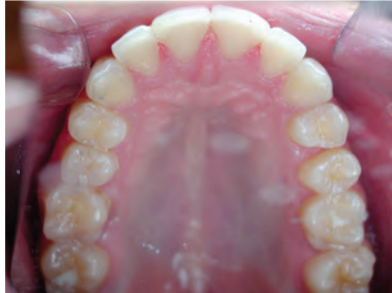
## ADOLESCENT TREATMENT

BEFORE



AFTER



*“I really like my new smile and bite.”*

—PATIENT’S COMMENT

## BRONSKY ORTHODONTICS

*“I don’t like the gap between my front teeth. Our dentist said my eye teeth never came in and I still have baby teeth.”*

—PATIENT’S CONCERNS

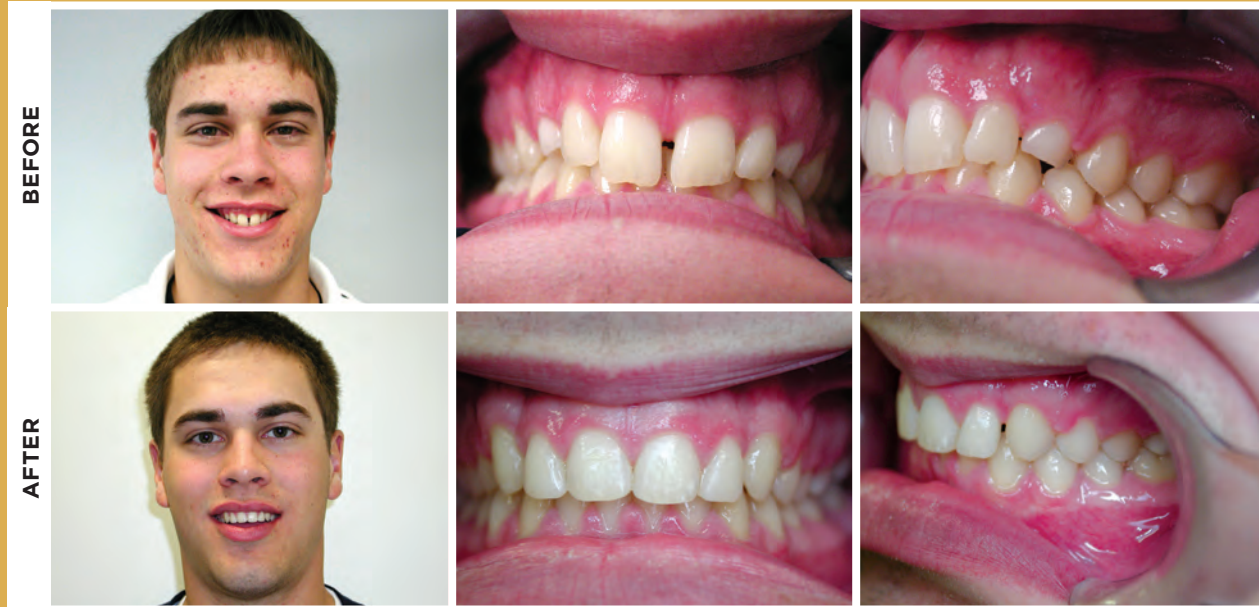### Orthodontic Problem List (Before)

- **Impacted** upper adult **canines** with retained ‘baby’ canines,
- **Midline space** between upper center front teeth,
- Overbite with **vertical overgrowth** of upper **front teeth**,
- **Excessive gum** display in full smile, and
- **Narrow smile** with dark spaces at corners.

### Treatment Accomplishments (After)

- Positioned impacted upper canines into dental arch,
- Repositioned front teeth upward while closing midline space,
- Eliminated gum exposure at smile, and
- Expanded upper dental arch for a broader smile.

## ADOLESCENT TREATMENT



*“I can’t believe how nice my smile looks.”*

—PATIENT’S COMMENT

*“My upper front teeth are out so far that I already chipped one.”*

—PATIENT'S CONCERNS

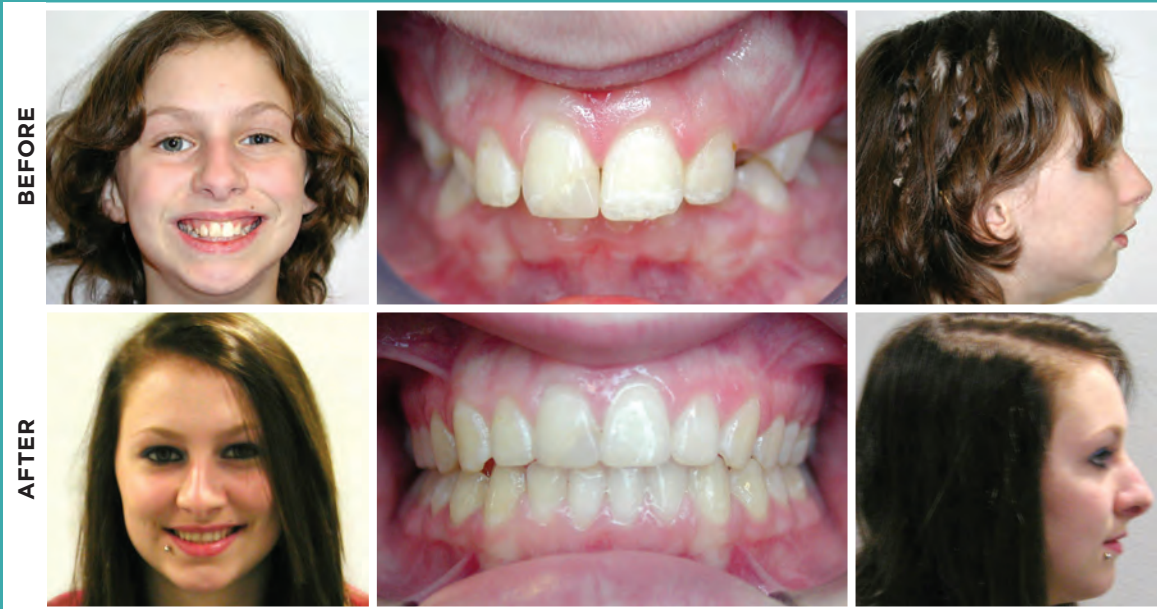### Orthodontic Problem List (Before)

- **Overbite** with lower front teeth biting into roof of mouth,
- **Protruding upper front teeth** with history of upper right tooth fracture due to trauma,
- Severe **lower jaw retrusion** (too far back), and
- Excessive tooth and **gum exposure** when smiling.

### Treatment Accomplishments (After)

- Overbite correction with functional contact of upper and lower front teeth,
- Reduction in forward position of upper front teeth,
- Dramatic improvement in facial profile including balanced jaw and lip relationships, and
- Beautiful smile with ideal front tooth exposure.

## ADOLESCENT TREATMENT



*“I love my new smile and bite and I am wearing my retainers to keep it that way.”*

—PATIENT'S COMMENT

*“My teeth are crowded and crooked and my dentist says I have a bad bite.”*

—PATIENT'S CONCERNS

### Orthodontic Problem List (Before)

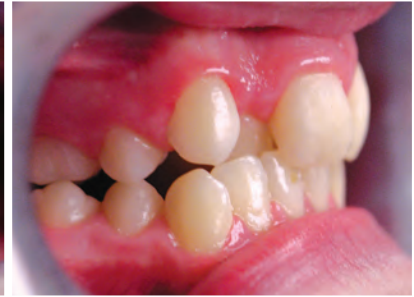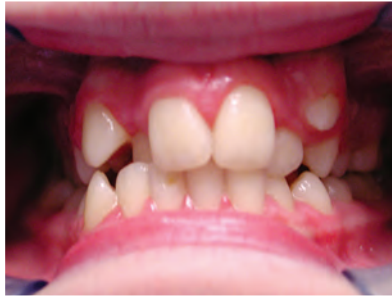- Upper **crowding** with outward position of upper canines,
- Inward **displacement** of upper side incisors resulting in a traumatic bite with lower front teeth and forward **lower jaw shift**,
- **Narrow upper jaw** associated with inward tipping of lower side teeth,
- **Traumatic** non-functional **bite** of right and left 'side' teeth, and
- Narrow smile with upper **front teeth offset** from center of face.

### Treatment Accomplishments (After)

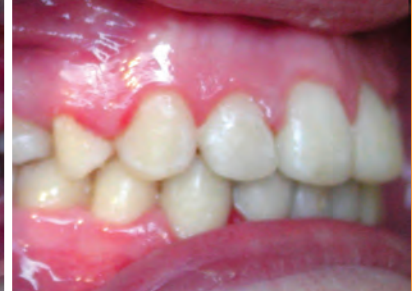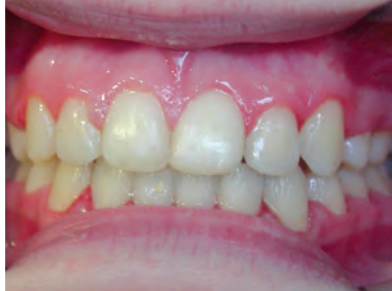- Alignment of upper and lower teeth with inward positioning of upper canines,
- Expansion of upper jaw and improved angulation of lower side teeth,
- Established a functional bite of front and side teeth, and
- Broadened smile and centered upper front teeth.

## ADOLESCENT TREATMENT

BEFORE



AFTER



*“I love my new smile, my relatives and friends can’t stop looking at my teeth.”*

—PATIENT’S COMMENT



*“My front teeth stick out and I have a big space between them.”*

—PATIENT'S CONCERNS

### Orthodontic Problem List (Before)

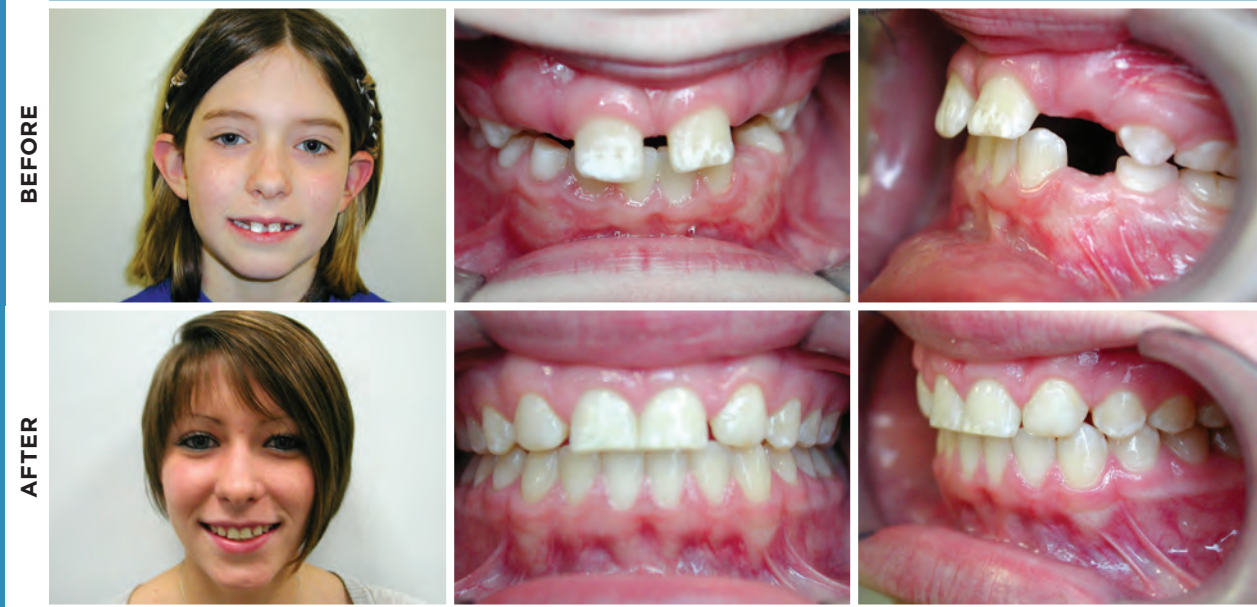- **Missing** upper adult **side incisors** due to genetic variability,
- **Spacing** between **protruded** upper center incisor teeth,
- **Traumatic** non-functional **bite** of 'side' teeth,
- Poor smile esthetics with **high risk of injury** to upper front teeth, and
- Developmentally related enamel irregularities (white spots).

### Treatment Accomplishments (After)

- Closure of space and retraction of upper center front teeth,
- Substitution of canines for missing side incisors,
- Forward movement of upper side teeth into a functional bite, and
- Significant improvement in smile—from two teeth to six teeth.



## ADOLESCENT TREATMENT



*“Thanks for closing my gap and giving me a pretty smile.”*

—PATIENT’S COMMENT

# BRONSKY ORTHODONTICS ADULT TREATMENT

The concerns motivating an adult to seek orthodontic treatment are complex and varied. Most adults want the ***attractive smile*** they missed by not having orthodontics when they were younger. As importantly, many adults seek orthodontic care because they are concerned about their ***dental health***.

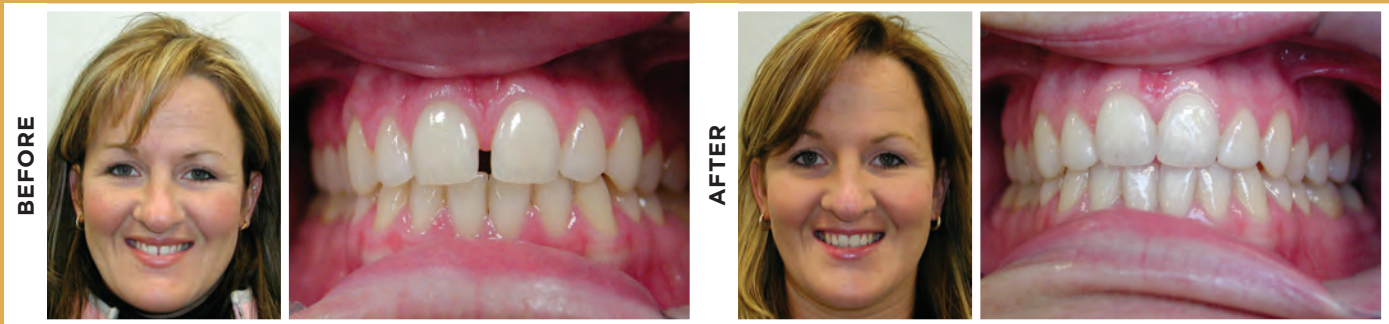A “bad bite” may compromise long-term dental health by resulting in abnormal wear of tooth surfaces and damage to supporting bone and gum tissue. Bite problems can also result in difficulty when eating, including pain when chewing.

Crowding and/or poorly spaced teeth can lead to excessive accumulation of plaque, often resulting in tooth decay, as well as gingivitis and the possible loss of supporting bone around the teeth. Therefore, a ‘bad bite’ and crowding/spacing problems may contribute to premature tooth loss and compromise long-term dental health. A cosmetically unattractive smile due to crowded, poorly spaced or protruding teeth can affect self-confidence. These orthodontic problems are amenable to correction by the Bronsky Orthodontics Adult Treatment Systems.

There are a number of **esthetic treatment** options that we utilize including customized clear aligners (an advanced adaptation of Invisalign™), as well as miniature clear brackets™ and low force (high comfort) advanced technology orthodontic wires.

*“I never liked my smile because of the gap  
between my front teeth.”*

—PATIENT'S CONCERNS



A beautiful smile  
following Bronsky Orthodontics  
esthetic adult treatment.

*“I do not like my twisted upper and lower front teeth and overbite.”*

—PATIENT'S CONCERNS

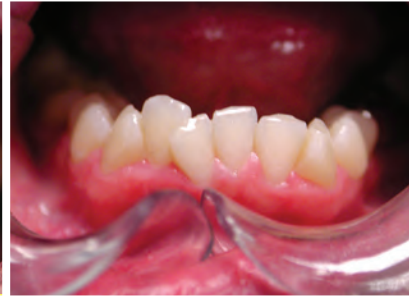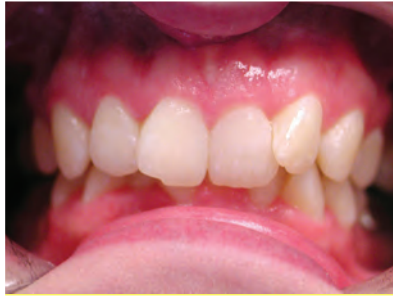### Orthodontic Problem List (Before)

- Moderate lower front tooth **crowding** with difficulty in maintaining proper oral hygiene, bone and gum health,
- Secondary to **overbite**, the lower front teeth are '**biting**' into the roof of her mouth causing pain when chewing, and
- **Crowding** of upper front teeth with inward **rotation** of center incisors and outward rotation of upper left side incisor.

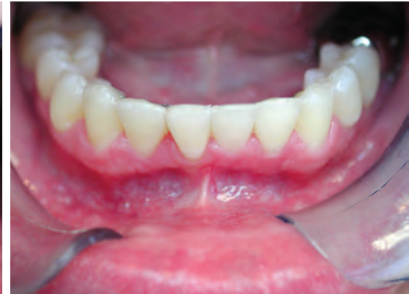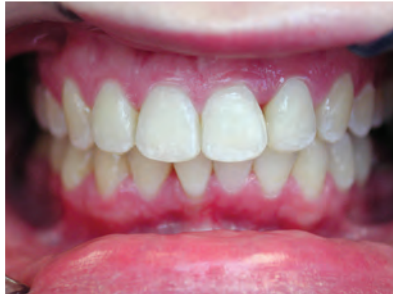### Treatment Accomplishments (After)

- Alignment of upper and lower front teeth,
- Smile enhancement after improved position of upper teeth, and
- Reduction in overbite with creation of functional contact between upper and lower front teeth.

BEFORE



AFTER



*“I love my new smile and it is a lot easier to brush and floss now that my teeth have been straightened.”*

—PATIENT’S COMMENT

## BRONSKY ORTHODONTICS

*“My teeth are crowded and overlapped and the upper front ones stick out too far.”*

—PATIENT'S CONCERNS

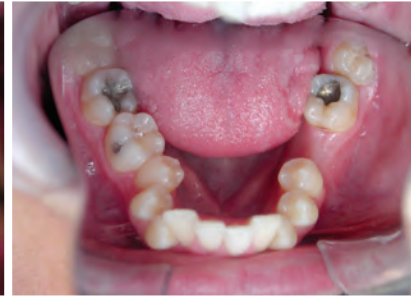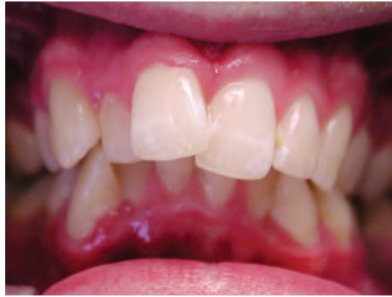### Orthodontic Problem List (Before)

- **Severe crowding** of upper and lower front teeth,
- **Protruding** and overlapped upper **front teeth**,
- **Narrow upper jaw** with inward angulation of lower side teeth,
- **Missing** lower left adult first molar,
- Dark spaces in corners of mouth with **constricted smile**, and
- **Difficulty** with **brushing and flossing** due to overlapped teeth.

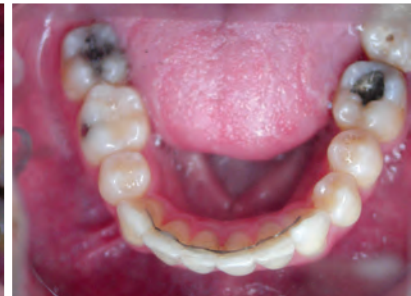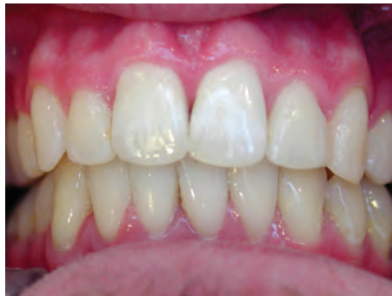### Treatment Accomplishments (After)

- Alignment of upper and lower front and side teeth,
- Broadening of upper and lower dental arches,
- Closure of lower first molar space to avoid a 'bridge' or implant,
- Significant improvement in smile, and
- Increased ability to maintain oral hygiene with brushing and flossing.

BEFORE



AFTER



*“I love my new smile and just in time for my wedding photos.”*

—PATIENT’S COMMENT

## BRONSKY ORTHODONTICS

*“The crowding of my lower front teeth is getting worse and I can’t brush and floss the way my dentist wants me to.”*

—PATIENT’S CONCERNS

### Orthodontic Problem List (Before)

- Lower front-tooth **crowding** with forward and backward **displacement**,
- **Overbite** with enamel wear of lower and upper front teeth, and
- **Traumatic bite** of side and front teeth.

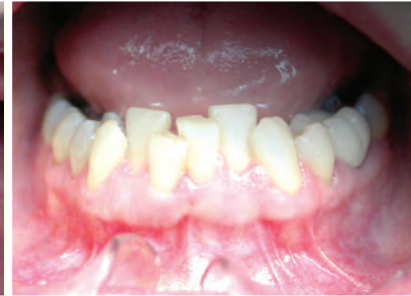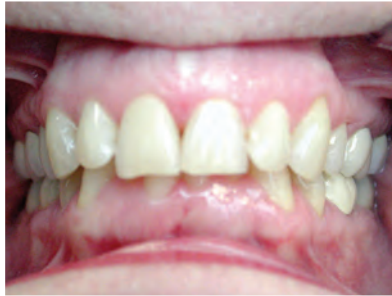### Treatment Accomplishments (After)

- Aligning of upper and lower front teeth,
- Correcting overbite and establishing functional contact between upper and lower front teeth, and
- Allowing for improved brushing and flossing to maintain dental health.

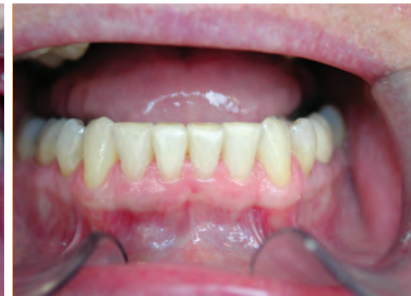
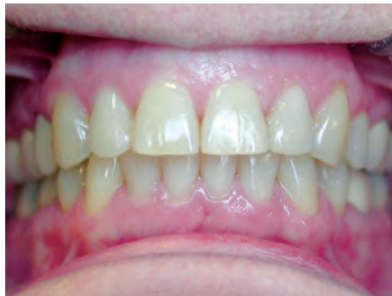
## ADULT TREATMENT

BEFORE



AFTER



*“Since you did such a great job on my two daughter’s orthodontic treatments, I could not wait for it to be my turn.”*

—PATIENT’S COMMENT

## BRONSKY ORTHODONTICS

*“My granddaughter, who is having her teeth straightened in California, had the idea for me to ‘get Invisalign’ to improve my smile at the same time.”*

—PATIENT'S COMMENT

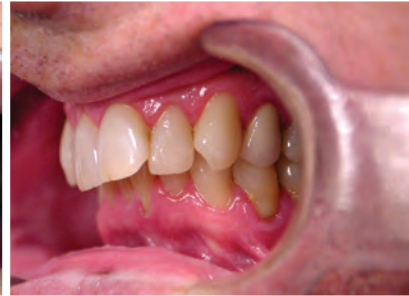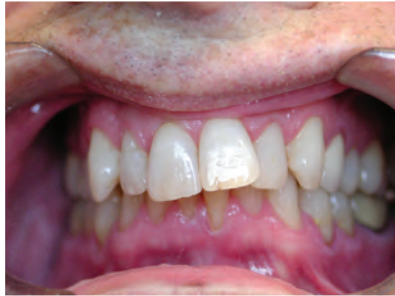### Orthodontic Problem List (Before)

- Upper and lower front tooth **crowding**,
- **Overbite** with enamel wear of lower front teeth,
- **Protruding** upper center front teeth which are tipped up to the left, and
- **Traumatic bite** of side and front teeth.

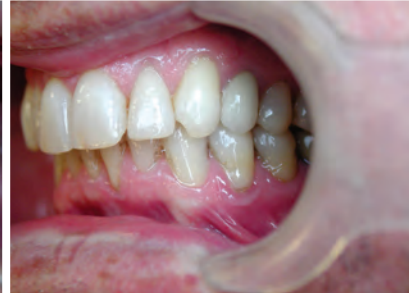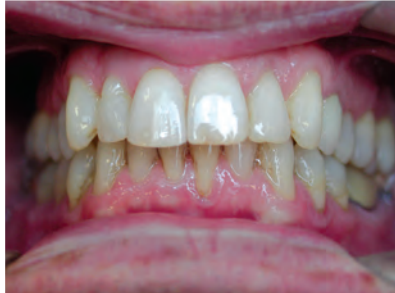### Treatment accomplishments utilizing Invisalign™ (clear aligner) System (After)

- Straightening of upper and lower front teeth and 'leveling' of smile line,
- Reducing overbite and improving contact between upper and lower front teeth, and
- Improving function of side teeth.

BEFORE



AFTER



*“I love my new smile. I am really happy that I had my teeth straightened. My granddaughter was right!”*

—PATIENT’S COMMENT

## BRONSKY ORTHODONTICS

*“I never liked to smile due to my ‘crooked’ teeth and my dentist thinks that difficulty with brushing and flossing contributed to loss of gum and bone support.”*

—PATIENT’S CONCERNS

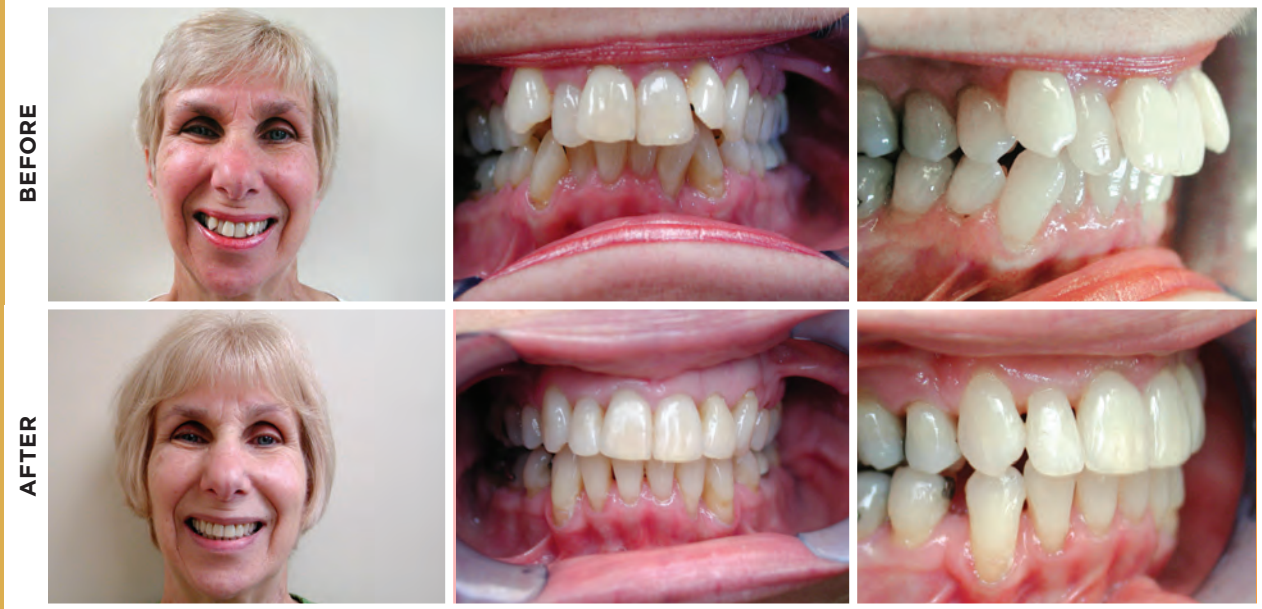### **Orthodontic Problem List (Before)**

- **Crowding** of upper and lower front teeth,
- **Traumatic ‘bite’** of front and side teeth, and
- **Bone loss** and gum recession.

### **Treatment Accomplishments (After)**

- Straightening and retraction of upper and lower front teeth,
- Improving function of front and side teeth, and
- Increasing ability for ideal oral hygiene to maintain dental health.

ADULT TREATMENT



*“I can’t stop smiling and my oral hygiene has improved.”*

—PATIENT’S COMMENT

*“My front teeth keep chipping away due to my bite and I am afraid that I will lose my teeth.”*

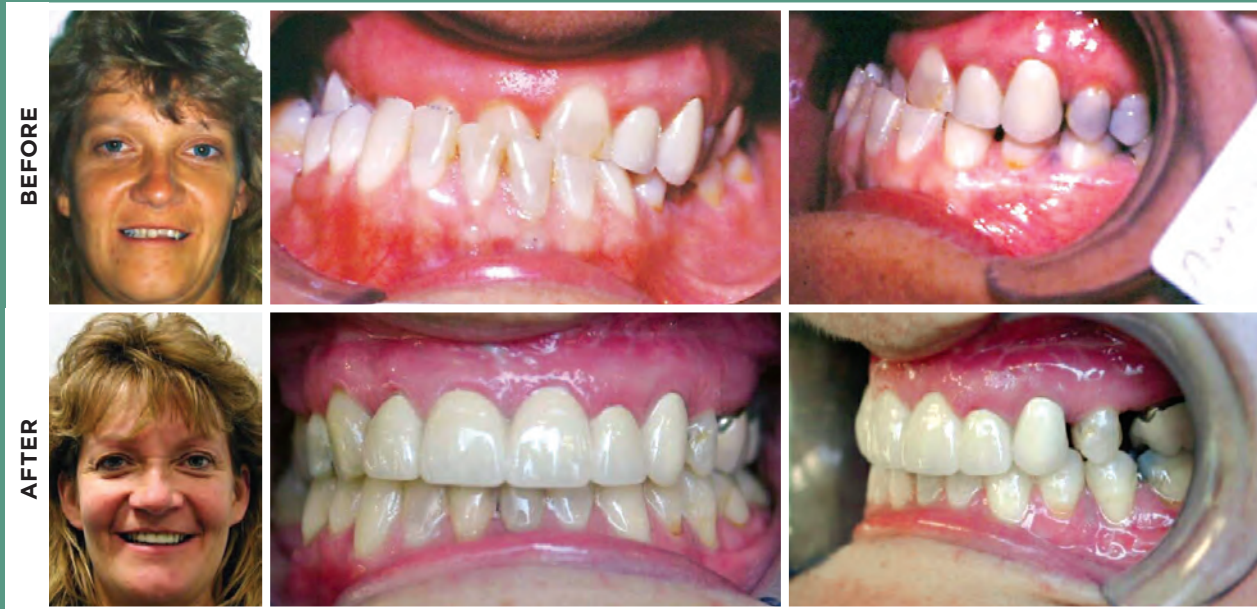—PATIENT'S CONCERNS

### Orthodontic Problem List (Before)

- Excessive **forward** position of **lower jaw**,
- **Elongated** lower **face height**,
- **Crossbite** of upper front and right side teeth, and
- Severe **uneven wear** of upper and lower **front teeth**.

### Treatment Accomplishments (After)

- Orthodontic treatment evened the heights of upper and lower front and side teeth to facilitate jaw surgery,
- Surgical rearrangement of upper and lower jaws to establish a functional bite including correction of crossbites (oral surgeon), and
- Restoration of teeth to improve contour and shape after a history of excessive wear (family dentist).



*“My new bite allows me to chew normally and I can smile like I’ve always wanted to. Best of all, my teeth are no longer wearing down and I plan on keeping them for the rest of my life.”*

—PATIENT’S COMMENT



*People of all ages and walks of life come to*  
**BRONSKY ORTHODONTICS**



*...and leave highly satisfied with their new healthy smiles!*



*Dentists bring their family members to*  
**BRONSKY ORTHODONTICS**



# DENTAL OFFICE PROFESSIONALS BRING THEIR FAMILY MEMBERS TO BRONSKY ORTHODONTICS!



*Reshaping Faces  
and Smiles  
for Your Future*

